Clínica Universitária de Radiologia

ELSEVIER

Available online at www.sciencedirect.com

ScienceDirect

EJSO 36 (2010) 725–730

EJSO
the Journal of Cancer Surgery

www.ejso.com

# Results of single-probe microwave ablation of metastatic liver cancer☆

R. Hompes [c], S. Fieuws [a,d], R. Aerts [c], M. Thijs [b], F. Penninckx [c], B. Topal [c,*]

[a] *Department of Biostatistics, Katholieke Universiteit Leuven, Belgium*
[b] *Department of Radiology, University Hospital Leuven, Herestraat 49, 3000 Leuven, Belgium*
[c] *Department of Abdominal Surgery, University Hospital Leuven, Herestraat 49, 3000 Leuven, Belgium*
[d] *Department of Biostatistics, Universiteit Hasselt, Belgium*

**Abstract**

*Aims*: Microwave ablation (MWA) is the most recent development in the field of local ablative therapies. The aim of this study was to evaluate the variability and reproducibility of single-probe MWA vs. radiofrequency ablation (RFA) of liver metastases smaller than 3 cm in patients without underlying liver disease.

*Methods*: Sixteen liver metastases were treated using MWA, and matched for size and localisation with 13 metastases treated by RFA. Tumour diameters and postoperative ablation diameters were recorded (D1 transverse; D2 antero-posterior; D3 cranio-caudal; mm) on computed tomography scans.

*Results*: Median D1, D2, and D3 ablation diameters after MWA vs. RFA were 18.5 (12–64) vs. 34 (16–41) mm ($p = 0.003$), 26 (14–60) vs. 35 (28–40) mm ($p = 0.046$), and 20 (10–73) vs. 32 (20–45) mm ($p = 0.025$), respectively. As compared to RFA, the variability between the lesions after MWA was significantly higher for D2 ($p < 0.0001$) and D3 ($p = 0.002$) but not for D1 ($p = 0.15$). The ablation diameters were less uniform after MWA than after RFA ($p < 0.001$).

*Conclusion*: Ablation diameters after single-probe MWA of metastatic liver tumours are highly variable and suboptimal. Improvements are needed before MWA can be implemented routinely.
© 2010 Elsevier Ltd. All rights reserved.

*Keywords:* Malignancy; Liver; Microwave; Surgery

- Ressecção cirúrgica é o “Gold Standard” para o tratamento das neoplasias primárias ou secundárias do fígado

- Contudo, muitos doentes não são candidatos a ressecção hepática
  - Limitações anatómicas
  - Doença multifocal
  - Insuficiência hepática (reserva)
  - Metástases extra-hepáticas
  - Comorbilidades

# Múltiplas terapêuticas ablativas (LAT)

- RFA
- MWA

# MWA - Vantagens (Teóricas)

- Maior zona de destruição tumoral
- Maior e mais constante a temperatura na lesão
- Mais rápida
- Possibilidade de vários eléctrodos/várias lesões
- Perda de calor provocada pelos vasos é menor

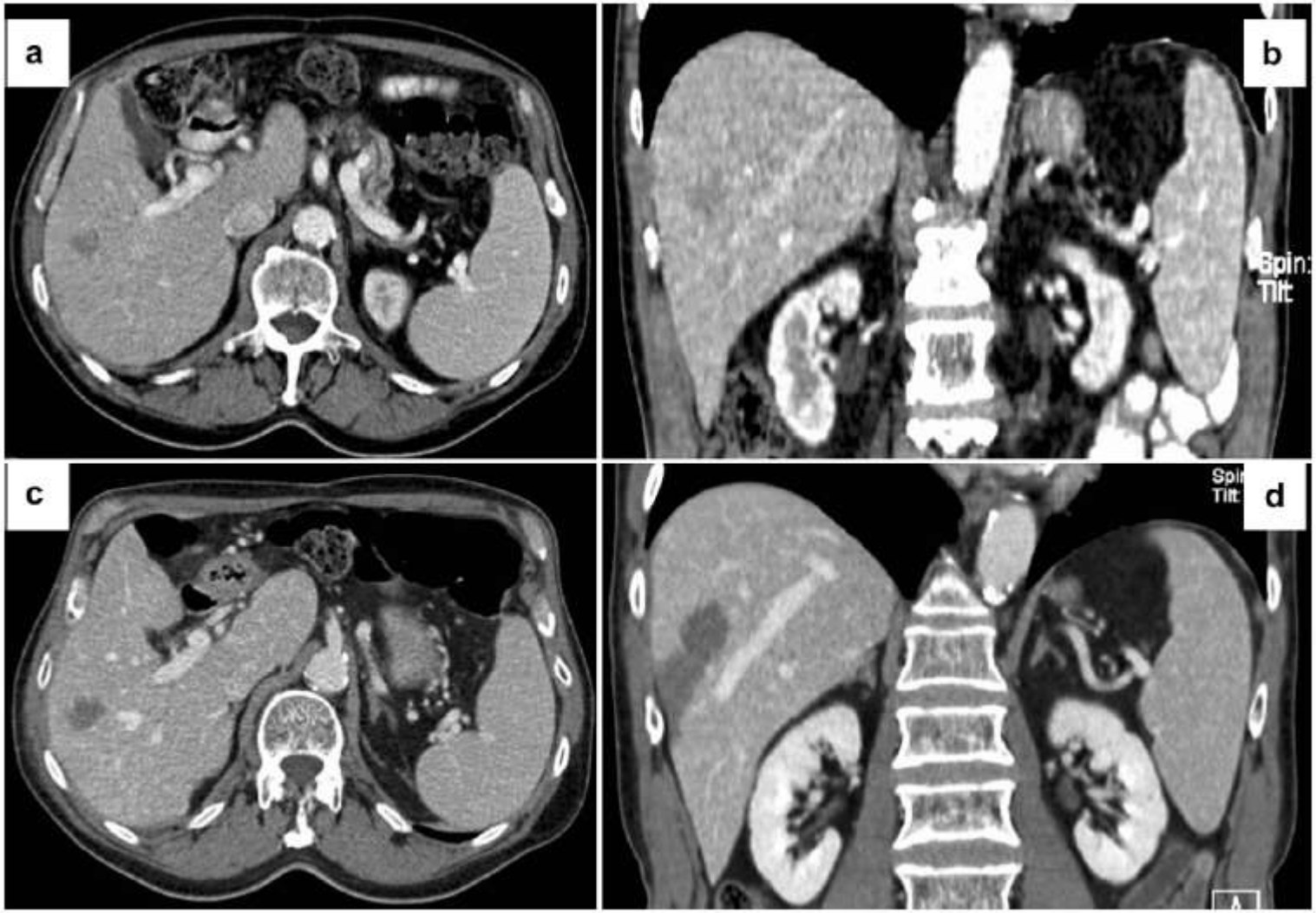


Figure 2. The 'comet effect' after microwave ablation (MWA) of liver tumours. Computed tomography scan showing a solitary liver metastasis from colorectal cancer in hepatic segment 5, in axial (a, c) and coronal (b, d) view before (a + b) and after (c + d) MWA.

# Imagiologia de Intervenção no tratamento do Carcinoma Hepatocelular
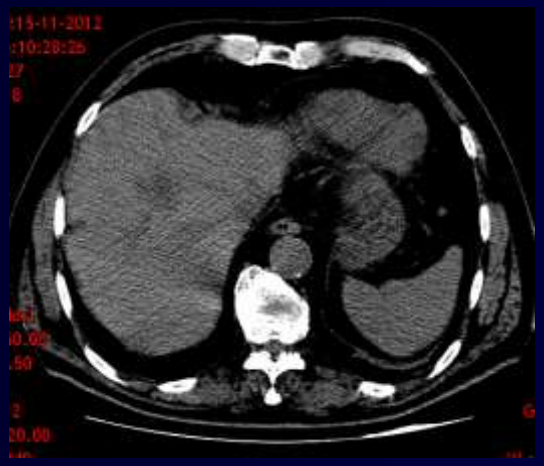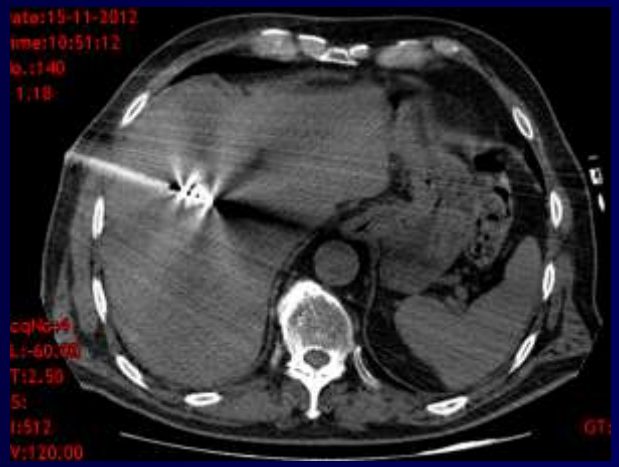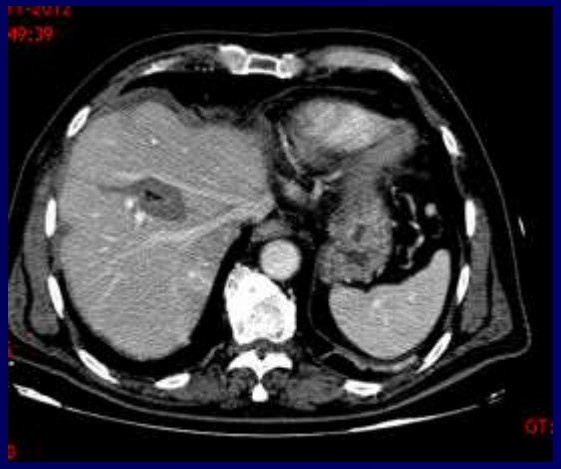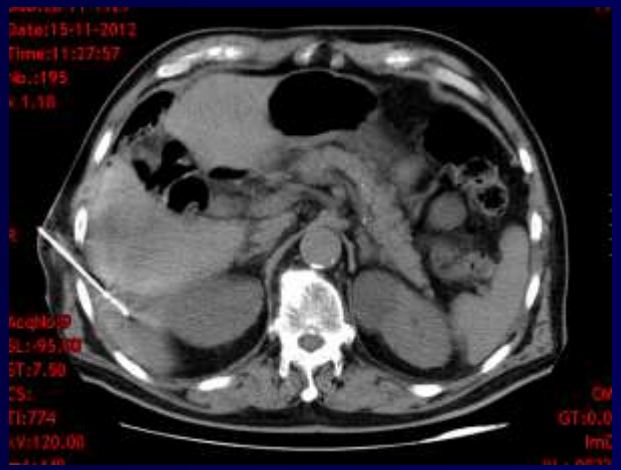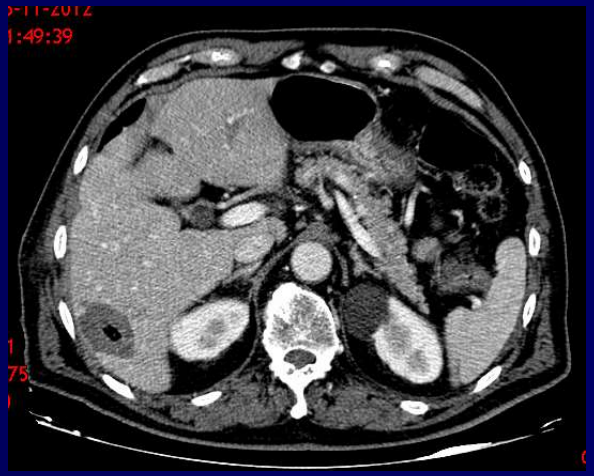
## Termoablação: MW